Pain Medicine, 21(4), 2020, 677–685
doi: 10.1093/pm/pnz225
Advance Access Publication Date: 14 September 2019
Original Research Article

OXFORD

Downloaded from https://academic.oup.com/painmedicine/article-abstract/21/4/677/5570559 by Univ of Ulsan, College of Med, Medical Library user on 16 April 2020

SPINE SECTION

Contrast Dispersion on Epidurography May Be Associated with Clinical Outcomes After Percutaneous Epidural Neuroplasty Using an Inflatable Balloon Catheter

Doo-Hwan Kim, MD,*[,a] Gyu Yeul Ji, MD,[†,a] Hyun-Jung Kwon, MD,* Taejun Na, MD,* Jin-Woo Shin, MD, PhD,* Dong Ah Shin, MD, PhD,[‡] and Seong-Soo Choi, MD, PhD*

*Department of Anesthesiology and Pain Medicine, Asan Medical Center, University of Ulsan College of Medicine, Seoul, Republic of Korea; †Department of Neurosurgery, Spine and Joint Research Institute, Guro Cham Teun Teun Hospital, Seoul, Republic of Korea; ‡Department of Neurosurgery, Spine and Spinal Cord Research Institute, Severance Hospital, Yonsei University College of Medicine, Seoul, Republic of Korea

[a]Equal contribution

Correspondence to: Dong Ah Shin, MD, PhD, Department of Neurosurgery, Spine and Spinal Cord Research Institute, Severance Hospital, Yonsei University College of Medicine, 50-1 Yonsei-ro, Seodaemun-gu, Seoul 03722, Republic of Korea. Tel: 82-2-2228-2174; Fax: 82-2-393-9979; E-mail: shindongah@me.com; and Seong-Soo Choi, MD, PhD, Department of Anesthesiology and Pain Medicine, Asan Medical Center, University of Ulsan College of Medicine, 88 Olympic-ro 43-gil, Songpa-gu, Seoul 05505, Republic of Korea. Tel: 82-2-3010-1538; Fax: 82-2-3010-6790; E-mail: choiss@amc.seoul.kr.

Funding sources: This research was supported by the SeongNam Industry Promotion Agency (Medi-Bio Product Development and Clinical Trial Support, 2017) and JUVENUI Co., Ltd.

Conflicts of interest: One of the authors (JWS) invented the ZiNeu catheter and transferred the patent to JUVENUI Co., Ltd., before submitting this manuscript.

Abstract

Background. Contrast dispersion pattern on epidurography may be associated with clinical improvement after epidural neuroplasty. However, insufficient evidence supports this theory. The current study aims to evaluate the relevance of contrast dispersion and clinical improvement after percutaneous epidural neuroplasty using an inflatable balloon catheter. **Methods.** One hundred patients with lumbar spinal stenosis who underwent combined balloon decompression and epidural adhesiolysis between March 2015 to December 2015 participated in the present study. Participants were divided into two groups by contrast dispersion pattern on postprocedural epidurography: the complete contrast dispersion (CCD) and incomplete contrast dispersion (ICCD) groups. The numeric rating scale (NRS), Oswestry Disability Index (ODI), and global perceived effects (GPE) were each assessed before and one, three, six, nine, and 12 months after the intervention. **Results.** After combined balloon decompression and adhesiolysis, significant pain reduction and functional improvement were maintained up to 12 months in patients with lumbar spinal stenosis. NRS and GPE in the CCD group were significantly lower than in the ICCD group from six to 12 months after the intervention. The ODI in the CCD group was also significantly lower compared with that in the ICCD group from one to 12 months after the intervention. **Conclusions.** Combined balloon decompression and adhesiolysis with the inflatable balloon catheter can provide noteworthy pain reduction and improvement of physical function for a long-term period in patients with lumbar spinal stenosis. Because CCD showed better clinical improvement compared with ICCD, a contrast dispersion pattern may be associated with an improved clinical outcome.

Key Words: Epidural Neuroplasty; Balloon Decompression; Contrast Dispersion; Lumbar Spinal Stenosis

© 2019 American Academy of Pain Medicine. All rights reserved. For permissions, please e-mail: journals.permissions@oup.com

Introduction

Lumbar spinal stenosis (LSS) refers to the anatomical narrowing of the spinal canal and is associated with a plethora of clinical symptoms, including pain in the lower back and extremities, impaired walking, and various forms of functional disability [1]. Treatment modalities for use with LSS vary, but it is sometimes difficult to treat. Recently, percutaneous epidural neuroplasty has been widely used in patients who fail with conventional treatment such as epidural steroid injections [2–4]. This technique is based on the lysis of microscopic adhesions surrounding nerve tissues and delivers therapeutic drugs directly to the target lesion [5].

Although many studies have shown the effects of epidural neuroplasty, only a few have reported the association between intraoperative fluoroscopic findings and interventional outcomes [6–8]. Pre- and postprocedural epidurography is always conducted during epidural neuroplasty, and postprocedural epidurography patterns are assumed to be indicators of interventional outcomes. The presence of poor contrast dispersion on postprocedural epidurography may be considered the requirement for repeat adhesiolysis procedures or more trials to achieve better contrast dispersion [9]. However, there is still insufficient evidence supporting the correlation between contrast dispersion and clinical outcome. Additionally, some evidence has demonstrated against a correlation between contrast dispersion and clinical outcomes [10–12].

Transforaminal balloon treatment has previously yielded significant pain relief and functional improvement in a subset of patients with refractory spinal stenosis [13]. Based on this research, the Zigzag-motion Inflatable Neuroplasty (ZiNeu, JUVENUI, Seongnam, Korea) catheter with an inflatable balloon was developed and introduced for percutaneous epidural adhesiolysis [14]. Although the ZiNeu catheter might be considered an effective alternative to percutaneous epidural adhesiolysis [15], it has only recently been developed and has not yet been used in many studies. Moreover, the relationship between contrast dispersion and clinical outcome after combined balloon decompression and adhesiolysis with the ZiNeu catheter has not been studied. Therefore, in the present study, we aimed to clarify the relevance of contrast dispersion on postprocedural epidurography and clinical improvement after combined balloon decompression and adhesiolysis with the ZiNeu catheter.

Methods

This was a prospective observational cohort study performed in a single spine specialty center in Seoul, Republic of Korea. We enrolled patients scheduled for combined percutaneous epidural adhesiolysis and balloon decompression using a balloon-inflatable catheter from March 2015 to December 2015. This study was approved by the institutional review board of Cham Teun Teun Hospital (approval number: 3190493AN01-201402-HR-010). Written informed consent was granted by all participant patients. The follow-up period was 12 months after the procedure.

Participants

A total of 100 patients with degenerative lumbar spinal stenosis were enrolled in this prospective study. Inclusion criteria were lumbar radicular pain with or without lower back pain and neurogenic spinal claudication with confirmed mild to severe spinal stenosis on lumbar magnetic resonance imaging (MRI) [16,17]. Exclusion criteria were a refusal to participate in the study, allergies to steroids or contrast dyes, systemic infection, malignancy, an unstable medical or psychiatric condition, pregnancy, lactation, and prior lumbar spine surgery.

Procedure: Percutaneous Epidural Decompression and Adhesiolysis Using an Inflatable Balloon Catheter

No sedatives or analgesics were administered before the intervention. The intervention was performed with the patient in the prone position on an operating table with a pillow beneath the abdomen to minimize lumbar lordosis. After sterile preparation and local infiltration with 1% lidocaine, a 10-G guide epidural needle was inserted into the caudal epidural space via the sacral hiatus under fluoroscopic guidance. Contrast medium (Omnipaque, Nycomed Imaging AS, Oslo, Norway) was injected to identify an epidural space. In case of contrast spread into the intravascular or subarachnoid space, the needle was immediately repositioned. After confirming proper guide needle position in the epidural space, an epidurogram was executed to evaluate the stenotic region in the epidural space as well as the filling defect, using approximately 5–8 mL of diluted contrast. Filling defects were identified by examining contrast dispersion.

After obtaining the appropriate target area on epidurography such as filling defects, a ZiNeu catheter was advanced through the guide needle to the target lesion. It was manipulated to reach the target site using advancement, withdrawal, rotation, and an intermittent bending of the catheter tip. Mechanical adhesiolysis and decompression were gently carried out at appropriate target sites as determined by epidurogram, location of pathology on lumbar MRI, and symptomatology. The ventral and dorsal epidural space, the lateral recess area, and each intervertebral foramen were the main target sites of decompressive neuroplasty with the ZiNeu catheter. The combined epidural adhesiolysis and balloon decompression were conducted using a gentle side-to-side movement of the catheter with intermittent ballooning. An inflatable balloon was attached to the end of the catheter tip. The balloon was filled with 0.13 mL of contrast

Downloaded from https://academic.oup.com/painmedicine/article-abstract/21/4/677/5570559 by Univ of Ulsan, College of Med, Medical Library user on 16 April 2020

agent using a 1-mL Luer-Lock syringe (BD Medical, Franklin Lakes, NJ, USA), and each period of ballooning was a maximum of five seconds. The extent of balloon inflation was limited for safety reasons if moderate to severe pain was noted. The catheter moved only when the balloon was in the deflated state. Sequential repeated inflation and deflation of the balloon were performed throughout the target region. After adhesiolysis and decompression, 1 mL of pure contrast was used to exclude subarachnoid or intravascular injection and to ensure mitigation of the previous filling defects. Then, 2 mL of 1% lidocaine with 5 mg of dexamethasone was administrated at each target site.

Classification of Contrast Dispersion on Postprocedural Epidurography

We classified contrast dispersion on postprocedural epidurography into complete contrast dispersion (CCD) and incomplete contrast dispersion (ICCD) groups. CCD was defined as when contrast medium had spread over all the target area, as determined by location of pathology on lumbar MRI (Figure 1), preprocedural epidurography, and clinical symptoms regardless of the target site or success of balloon inflation (Figure 2). It also included epidural filling defects on a preprocedural epidurography that were resolved on postprocedural epidurography. Unless specifically noted, all the other contrast spread patterns were defined as ICCD.

Assessment of Interventional Outcomes and Follow-up

All patients were clinically evaluated before and one, three, six, nine, and 12 months after combined epidural adhesiolysis and balloon decompression by a verified nurse specialist in pain management. The intensity of leg and back pain was assessed using an 11-point numeric rating scale (NRS; 0 = no pain, 10 = worst pain imaginable). To assess physical function, the Korean version of the 10-item Oswestry Disability Index (ODI) questionnaire was used [18]. Each question was scored from 0 to 5, with 0 representing either the best outcome and/or the fewest symptoms. The scores from each question were summed to yield overall scores ranging from 0 to 50. The total scores were converted to a scale of 0 to 100 points. The Beck Depression Inventory was also assessed to evaluate emotional status [19]. Additionally, global perceived effects, measured on a seven-point scale (GPE; 1 = worst ever, 7 = best ever), were utilized to assess patient satisfaction [20]. Before the procedure, participants were instructed how to measure NRS, ODI, BDI, and GPE for precise evaluation. Complications and any adverse events during the intervention and follow-up period were all recorded.

Statistical Analysis

All continuous variables were tested for normality using the Kolmogorov-Smirnov test. BDI scores were compared using Student *t* tests and expressed as the mean ± standard deviation. Age and body mass index (BMI) were compared using Mann-Whitney *U* tests and presented as the median and interquartile range. Categorical data including gender, underlying diseases, type and grade of spinal stenosis, and presence of spondylolisthesis were presented as numbers and percentages and compared using the chi-square test. For multiple comparisons, two-way repeated-measures analyses of variance followed by post hoc analysis with Bonferroni correction were used to compare differences in NRS, ODI, and GPE from baseline to one, three, six, nine, and 12 months after the procedure. Conventional P values for single testing of <0.05 and corrected P values for multiple testing using Bonferroni correction of <0.008 were considered statistically significant. Data were analyzed using the Statistical Package for the Social Sciences (SPSS, version 21.0; IBM SPSS Statistics, IBM Corporation, Armonk, NY, USA).

Results

A total of 100 patients participated in the present study. Baseline demographic and clinical characteristics are shown in Table 1. The patients were classified into CCD and ICCD groups according to the contrast dispersion on postprocedural epidurography. Fifty-four patients were included in the CCD group, and 46 patients were included in the ICCD group. All patients were finally analyzed without loss to follow-up. There were no significant differences between the two groups in clinical characteristics.

The intensity of back and leg pain in both groups was significantly reduced as compared with baseline values throughout the 12 months after the procedure (Table 2, Figure 3A and B). The NRS in the CCD group was significantly lower than in the ICCD group at six, nine, and 12 months after the procedure.

Physical function in both groups was also significantly improved as compared with baseline values throughout the 12 months after the procedure (Table 2, Figure 3C). The ODI in the CCD group was significantly lower than in the ICCD group at all measurement time points during the follow-up period.

Each group was subdivided into three groups according to ≥30%, ≥50%, and 100% relief of pain. The numbers of patients who had decreased back and leg pain ≥30% and ≥50% compared with baseline value were significantly higher in the CCD group than in the ICCD group after the procedure (Tables 3 and 4). Although four patients had no back pain at 12 months after the procedure in the CCD group, there was no difference between both groups in patients who achieved complete relief of pain (Table 3).

Downloaded from https://academic.oup.com/painmedicine/article-abstract/21/4/677/5570559 by Univ of Ulsan, College of Med, Medical Library user on 16 April 2020

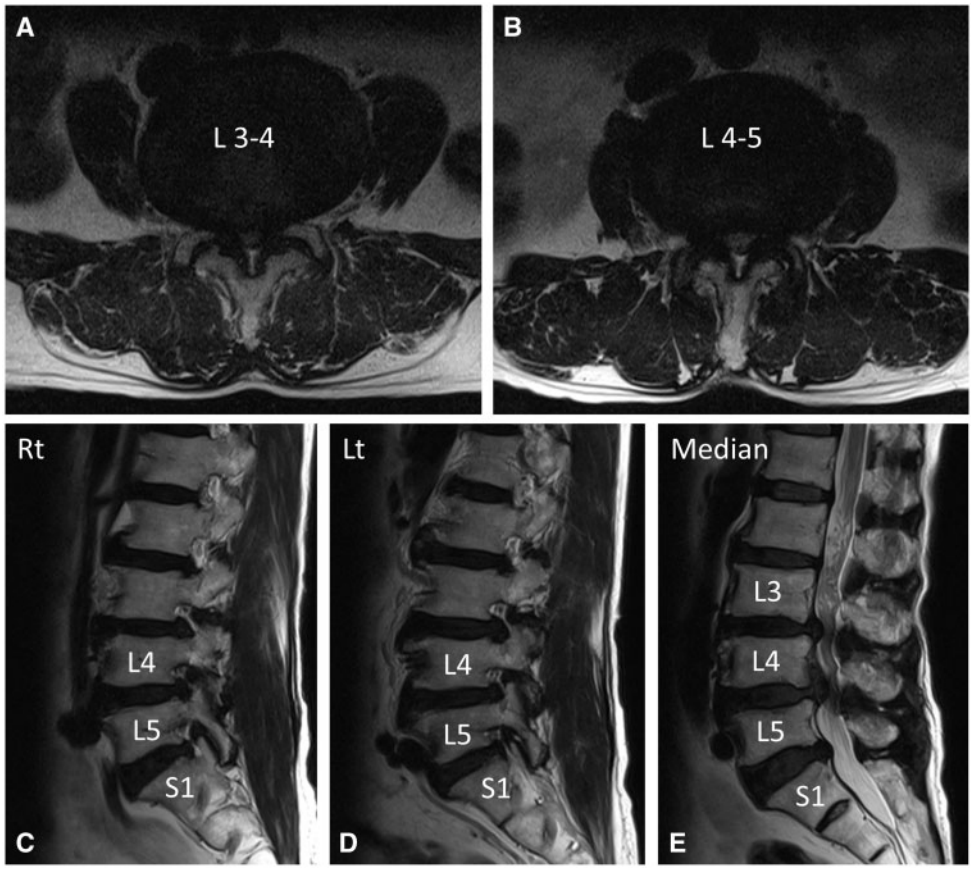

Figure 1. Preoperative lumbar magnetic resonance images (MRIs) of the patient (55-year-old female), who complained of low back pain and sciatica (both L5 dermatomes). A, B) The T2-weighted axial MRIs at L3–4 and L4–5 showed moderate to severe central spinal stenosis. C, D, E) The T2-weighted sagittal MRIs showed bilateral neural foraminal stenosis at L5–S1 (C and D) and central spinal stenosis at L3–4 and L4–5 (E).

As shown in Table 2, the patient satisfaction scores in both groups were not different at one month. However, the GPE in the CCD group was significantly lower than in the ICCD group at six and 12 months after the procedure. There were no complications or adverse events during the intervention and follow-up periods.

Discussion

There are two main findings in the present study. First, the combined balloon decompression and adhesiolysis with the ZiNeu catheter provided significant pain relief and improvement of physical function in the patients with lumbar spinal stenosis for up to 12 months. Second, complete contrast dispersion on postprocedural epidurography showed better pain relief, functional outcomes, and patient satisfaction than incomplete contrast dispersion.

Combined balloon decompression and adhesiolysis with the ZiNeu catheter have a unique advantage for epidural adhesiolysis. As this procedure can more greatly distend the stenotic lesion using a balloon, it can remove perineural adhesions and reduce mechanical irritation and venous congestion more effectively compared with conventional epidural adhesiolysis [13]. Recently, several studies have reported the effect of combined balloon decompression and adhesiolysis in patients with lumbar spinal stenosis [13–15]. The present study also shows that a decrease of pain intensity in both the back and legs, improvement in physical function, and high patient satisfaction were maintained for 12 months after the intervention, similar to a previous prospective observational study [15]. Therefore, it may be an effective and suitable epidural neuroplasty method in patients with lumbar spinal stenosis.

Many prior studies have shown a correlation between contrast dispersion on postprocedural epidurography and clinical outcomes [9,21,22]. However, it is still unclear how the contrast dispersion pattern affects clinical outcomes in patients who have undergone lumbar epidural neuroplasty, especially for those who have undergone balloon decompression and adhesiolysis.

According to a previous study, among the total number of patients with lumbar spinal stenosis, 35% had more than two levels of moderate to severe stenosis [23]. Degenerative spondylolisthesis occasionally leads to the central canal, with lateral recess or foraminal stenosis at multiple levels. The neurogenic claudication is thought to

Downloaded from https://academic.oup.com/painmedicine/article-abstract/21/4/677/5570559 by Univ of Ulsan, College of Med, Medical Library user on 16 April 2020

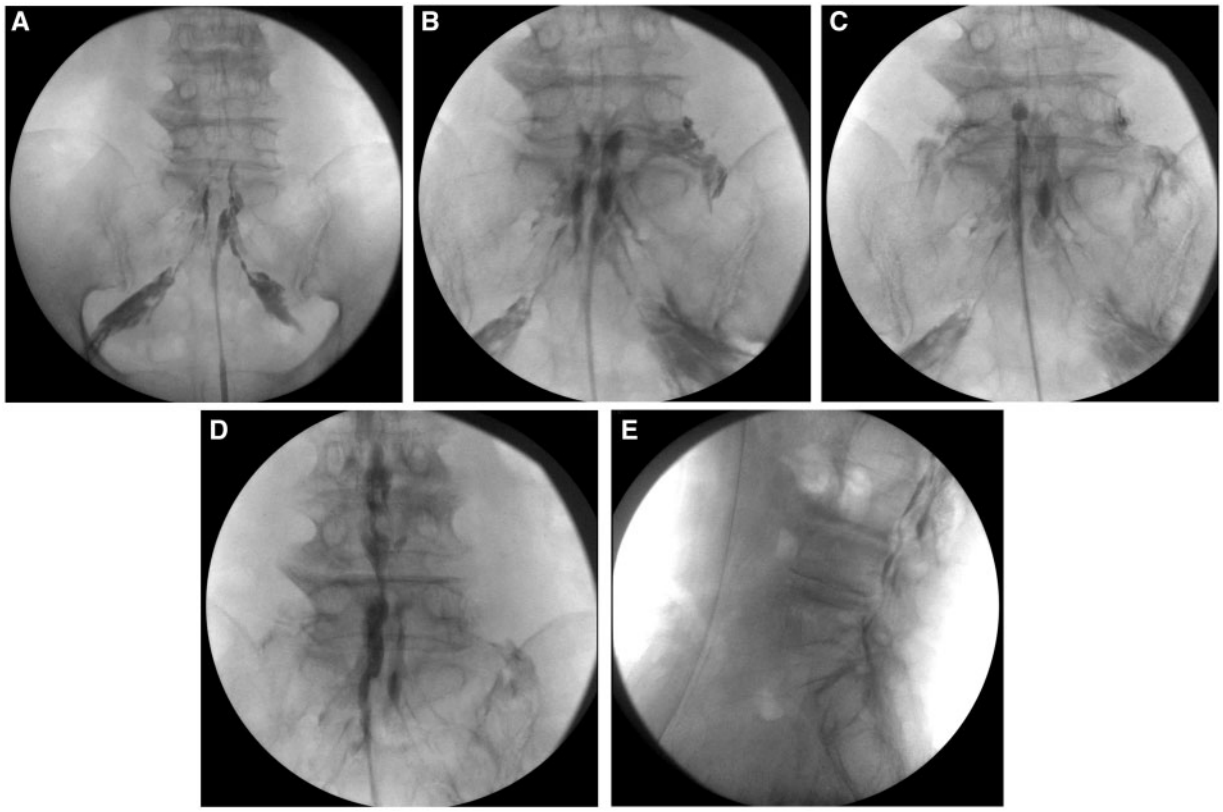

Figure 2. Representative epidurography for demonstrating complete contrast dispersion. Preprocedural epidurography (A) and postprocedural epidurography (B, C, D, and E) during combined balloon decompression and adhesiolysis. It presented filling defects above L5–S1 (A). Contrast medium was spread at the right and left foramina of L5–S1 (B, C). It also spread into the central, anterior, and posterior epidural space over L5–S1 after combined balloon decompression and adhesiolysis (D, E), and the filling defects on preprocedural epidurography were resolved. Contrast medium spread over all the target area as determined by location of pathology on lumbar magnetic resonance imaging, preprocedural epidurography, and clinical symptoms.

Table 1. Study patient characteristics

	Total (N = 100)	Complete Contrast Dispersion (N = 54)	Incomplete Contrast Dispersion (N = 46)	*P* Value
Age, y	61.5 [54.0–71.0]	59.0 [53.0–69.0]	64.5 [56.0–72.0]	0.051
Gender (M/F)	43 (43.0)/57 (57.0)	23 (42.6)/31 (57.4)	20 (43.5)/26 (56.5)	1.000
Body mass index, kg/m^2	24.8 [22.9–25.5]	24.7 [22.9–25.8]	24.8 [22.9–25.5]	0.715
Diabetes	8 (8.0)	2 (3.7)	6 (13.0)	0.138
Hypertension	24 (18.5)	13 (24.1)	10 (21.7)	0.816
Previous adhesiolysis	11 (11.0)	5 (9.3)	6 (13.0)	0.778
Spinal stenosis (central/foraminal/both)	18 (18.0)/67 (67.0)/15 (15.0)	12 (22.2)/37 (68.5)/5 (9.3)	6 (13.0)/30 (65.2)/10 (21.7)	0.151
Stenosis grade (mild to moderate/severe)	78 (78.0)/22 (22.0)	46 (85.2)/8 (14.8)	32 (69.6)/14 (30.4)	0.089
Spondylolisthesis	3 (3.0)	1 (1.9)	2 (4.3)	0.888
Beck Depression Index	5.5 ± 1.7	5.4 ± 1.6	5.7 ± 1.7	0.388

Data are expressed number (%), mean ± SD, or median [interquartile range].

result from compression on the vertebral venous plexus from multilevel stenosis that creates venous pooling and congestion, leading to ischemic pain and fatigue in the lower extremities during walking [24]. Hence, many patients with lumbar spinal stenosis have multiple stenotic lesions. As proper contrast spread related to the target site would be considered an indicator of successful interventional outcomes [25], we speculated that CCD might be mandatory to achieve successful epidural neuroplasty.

Park et al. suggested that extraforaminal contrast distribution during lumbar epidural neuroplasty may be

Downloaded from https://academic.oup.com/painmedicine/article-abstract/21/4/677/5570559 by Univ of Ulsan, College of Med, Medical Library user on 16 April 2020

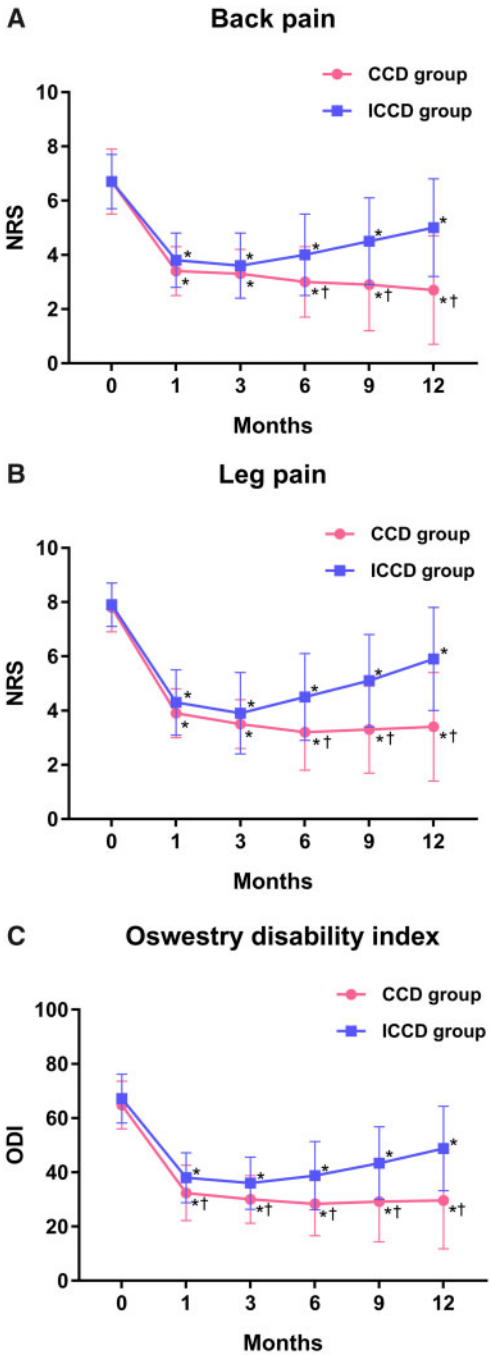

Figure 3. Comparisons of numerical rating scale scores of back (A) and leg (B) and Oswestry Disability Index scores (C) between the complete contrast dispersion (blue square) group and the incomplete contrast dispersion (red circle) group during the follow-up time period after the intervention. The blue square and red circle represent the mean value in each group. The error bars represent the standard deviation of the mean. *$P<0.05$ compared with baseline values in each group. †$P<0.008$ (Bonferroni-corrected significance level) compared with the ICCD group.

associated with better functional outcomes [9]. Similarly, Han et al. proved that a contrast runoff pattern correlates with the clinical outcome in cervical epidural neuroplasty using a Racz catheter [21]. Moreover, a contrast spread

Table 2. Pain, functional outcomes, and patient satisfaction after epidural neuroplasty using an inflatable balloon catheter

Feature	Follow-up, mo	Group: CCD (N = 54)	Group: ICCD (N = 46)	*P* Value
Back pain (NRS: 0 – 10)	0 (baseline)	6.7 ± 1.2	6.7 ± 1.0	0.994
	1	3.4 ± 0.9*	3.8 ± 1.0*	0.026
	3	3.3 ± 0.9*	3.6 ± 1.2*	0.153
	6	3.0 ± 1.3*,†	4.0 ± 1.5*	0.001
	9	2.9 ± 1.7*,†	4.5 ± 1.6*	<0.001
	12	2.7 ± 2.0*,†	5.0 ± 1.8*	<0.001
Leg pain (NRS: 0–10)	0 (baseline)	7.8 ± 0.9	7.9 ± 0.8	0.667
	1	3.9 ± 0.9*	4.3 ± 1.2*	0.067
	3	3.5 ± 0.9*	3.9 ± 1.5*	0.123
	6	3.2 ± 1.4*,†	4.5 ± 1.6*	<0.001
	9	3.3 ± 1.6*,†	5.1 ± 1.7*	<0.001
	12	3.4 ± 2.0*,†	5.9 ± 1.9*	<0.001
ODI (0 – 100)	0 (baseline)	64.8 ± 8.8	67.2 ± 9.0	0.196
	1	32.4 ± 10.2*,†	38.0 ± 9.2*	0.005
	3	30.0 ± 8.8*,†	36.0 ± 9.6*	0.002
	6	28.4 ± 11.8*,†	38.8 ± 12.6*	<0.001
	9	29.2 ± 14.8*,†	43.4 ± 13.4*	<0.001
	12	29.6 ± 17.8*,†	48.8 ± 15.6*	<0.001
GPE (1–7)	1 (baseline)	5.3 ± 0.5	5.2 ± 0.6	0.204
	6	5.4 ± 0.6*,†	4.8 ± 0.8*	<0.001
	12	5.3 ± 0.9*,†	4.2 ± 1.0*	<0.001

Mean scores (±SD) for back pain, leg pain, Oswestry Disability Index, and global perceived effect of patients treated by epidural neuroplasty using an inflatable balloon catheter, according to whether dispersal of contrast medium after treatment was complete or incomplete.

CCD = complete contrast dispersion; GPE = global perceived effect; ICCD = incomplete contrast dispersion; NRS = numeric rating scale; ODI = Oswestry Disability Index.

*$P < 0.05$ compared with baseline values in each group.

†$P < 0.008$ (Bonferroni-corrected significance level) compared with the ICCD group.

pattern into the lateral and medial foramen showed significant postprocedural pain reduction in cervical epidural steroid injections compared with the extraforaminal spread pattern [22]. In the present study, we also observed a significant difference in pain intensity and clinical improvement in favor of complete contrast dispersion compared with incomplete contrast dispersion (Figure 3). The number of patients with back and leg pain that decreased by more than 30% or 50% was significantly higher in the CCD group than in the ICCD group during the follow-up period after the procedure (Tables 2 and 3). In other words, in the CCD group, but not the ICCD group, back and leg pain was reduced throughout the follow-up period. This result was consistent with the above analyses, suggesting that proper contrast dispersion relevant to all target lesions can ensure successful outcomes after combined balloon decompression and adhesiolysis.

However, some studies suggest the opposite opinion, showing that contrast dispersion was not relevant to pain reduction in patients who underwent cervical transforaminal epidural steroid injection or percutaneous epidural adhesiolysis [10,11]. Devulder et al. reported that a better spread of contrast did not guarantee sustained pain

Downloaded from https://academic.oup.com/painmedicine/article-abstract/21/4/677/5570559 by Univ of Ulsan, College of Med, Medical Library user on 16 April 2020

Table 3. Observed number of patients with decreased pain intensity for back pain

	Complete Contrast Dispersion (N = 54)			Incomplete Contrast Dispersion (N = 46)		
	Decreased Pain Intensity			Decreased Pain Intensity		
Follow-up	≥30%	≥50%	100%	≥30%	≥50%	100%
1 mo	47 (87.0)	34 (63.0)*	0 (0)	35 (76.1)	16 (34.8)	0 (0)
3 mo	50 (92.6)	38 (70.4)	0 (0)	36 (78.3)	27 (58.7)	0 (0)
6 mo	48 (88.9)*	38 (70.4)*	0 (0)	30 (65.2)	19 (41.3)	0 (0)
9 mo	44 (81.5)*	38 (70.4)*	0 (0)	26 (56.5)	9 (19.6)	0 (0)
12 mo	44 (81.5)*	39 (72.2)*	4 (7.4)	17 (37.0)	11 (23.9)	0 (0)

Data are expressed as number (%).
*$P < 0.05$ compared between groups.

Table 4. Observed number of patients with decreased pain intensity for leg pain

	Complete Contrast Dispersion (N = 54)			Incomplete Contrast Dispersion (N = 46)		
	Decreased Pain Intensity			Decreased Pain Intensity		
Follow-up	≥30%	≥50%	100%	≥30%	≥50%	100%
1 mo	54 (100.0)*	32 (59.3)	0 (0)	35 (76.1)	18 (39.1)	0 (0)
3 mo	52 (96.3)	43 (79.6)	0 (0)	39 (84.8)	30 (65.2)	0 (0)
6 mo	50 (92.6)*	44 (81.5)*	0 (0)	30 (65.2)	21 (45.7)	0 (0)
9 mo	48 (88.9)*	42 (77.8)*	0 (0)	24 (52.2)	14 (30.4)	0 (0)
12 mo	44 (81.5)*	39 (72.2)*	0 (0)	16 (34.8)	11 (23.9)	0 (0)

Data are expressed as number (%).
*$P < 0.05$ compared between groups.

relief in epidural neuroplasty [12]. They insisted that a therapeutic injection might eventually reach the target lesion, despite a lack of proper contrast dispersion. Additionally, because filling defects on epidurography may be attributable to nonpathologic scars or functional adhesions, resolution of the filling defect may not be associated with an improvement in clinical outcome. However, epidural neuroplasty is believed to result from either adhesiolysis or decompression, both of which lead to improved targeting of drug delivery and subsequent therapeutic effects in patients with refractory pain not relieved by conventional intervention [26]. Moreover, epidurography is generally considered a very useful and frequently used diagnostic method to check for epidural adhesion [27]. From this point of view, several studies have demonstrated a relevant correlation between the filling defect and clinical manifestations [26,28–30]. Therefore, complete contrast dispersion may ensure that injectates reach the target lesion. That is, complete contrast dispersion may lead to a better clinical outcome after combined balloon decompression and adhesiolysis. Reasonably, we tried to achieve complete contrast dispersion in the patients of this study. However, anatomical difficulties including bony spur and severe spinal stenosis and the unbearable pain during the procedure were major causes of the remaining incomplete contrast dispersion. Further studies about the relationship between contrast dispersion and clinical outcome are required.

There are several possible limitations to this study. First, as the list of patients' medications before the intervention was missed in our survey, we could not quantify medications used to treat a variety of pain conditions. Quantifying pain medication regimens may be important and necessary during the follow-up period after the intervention, because it may indicate the condition of the patient being treated. Although quantifying pain medication could not be presented, we tried various assessments including the NRS, ODI, and GPE for more appropriately reflecting clinical improvement during long-term follow-up. Second, the effect of the combined balloon decompression and adhesiolysis may be attributed to the combined effect of ballooning, the administration of various drugs, and flushing with saline. The effects of local anesthetics, steroids, and saline washes are usually short-lived [31], but clinical improvement persisted for up to 12 months in the present study. The long-term effects (i.e., greater than six months) of conventional epidural neuroplasty are uncertain and controversial [32]. For the above reasons, we suggest that the ballooning alone, not other factors, could lead to long-term improvement of clinical outcomes when performing combined balloon decompression and adhesiolysis.

Downloaded from https://academic.oup.com/painmedicine/article-abstract/21/4/677/5570559 by Univ of Ulsan, College of Med, Medical Library user on 16 April 2020

Conclusions

Combined balloon decompression and adhesiolysis with the ZiNeu catheter can provide significant pain relief and functional improvement for up to 12 months in patients with lumbar spinal stenosis. Because combined balloon decompression and adhesiolysis with complete contrast dispersion showed greater clinical improvement compared with incomplete contrast dispersion, contrast dispersion may be associated with an improvement of clinical outcome. Therefore, when performing epidural neuroplasty, especially with a ZiNeu catheter, complete contrast dispersion needs to be present to ensure a successful outcome.

References

1. Siebert E, Prüss H, Klingebiel R, Failli V, Einhäupl KM, Schwab JM. Lumbar spinal stenosis: Syndrome, diagnostics and treatment. Nat Rev Neurol 2009;5(7):392–403.
2. Hsu E, Atanelov L, Plunkett AR, Chai N, Chen Y, Cohen SP. Epidural lysis of adhesions for failed back surgery and spinal stenosis: Factors associated with treatment outcome. Anesth Analg 2014;118(1):215–24.
3. Jamison DE, Hsu E, Cohen SP. Epidural adhesiolysis: An evidence-based review. J Neurosurg Sci 2014;58(2):65–76.
4. Lee F, Jamison DE, Hurley RW, Cohen SP. Epidural lysis of adhesions. Korean J Pain 2014;27(1):3–15.
5. Racz GB, Heavner JE, Trescot A. Percutaneous lysis of epidural adhesions-evidence for safety and efficacy. Pain Pract 2008;8(4):277–86.
6. Ji GY, Oh CH, Moon B, et al. Efficacy of percutaneous epidural neuroplasty does not correlate with dural sac cross-sectional area in single level disc disease. Yonsei Med J 2015;56(3):691–7.
7. McLain RF, Kapural L, Mekhail NA. Epidural steroid therapy for back and leg pain: Mechanisms of action and efficacy. Spine J 2005;5(2):191–201.
8. Moon SH, Lee JI, Cho HS, Shin JW, Koh WU. Factors for predicting favorable outcome of percutaneous epidural adhesiolysis for lumbar disc herniation. Pain Res Manag 2017;2017:1494538.
9. Park SH, Ji GY, Cho PG, et al. Clinical significance of epidurography contrast patterns after adhesiolysis during lumbar percutaneous epidural neuroplasty. Pain Res Manag 2018;2018:6268045.
10. Park CH, Lee SH. Contrast dispersion pattern and efficacy of computed tomography-guided cervical transforaminal epidural steroid injection. Pain Physician 2014;17(6):487–92.
11. Hong Park C, Ho Lee S. Epidurographic findings following percutaneous epidural adhesiolysis failed to correlate with level of pain reduction in patients with lumbar spinal stenosis. Pain Med 2017;18(5):842–5.
12. Devulder J, Bogaert L, Castille F, Moerman A, Rolly G. Relevance of epidurography and epidural adhesiolysis in chronic failed back surgery patients. Clin J Pain 1995;11(2):147–50.
13. Kim SH, Choi WJ, Suh JH, et al. Effects of transforaminal balloon treatment in patients with lumbar foraminal stenosis: A randomized, controlled, double-blind trial. Pain Physician 2013;16(3):213–24.
14. Choi SS, Joo EY, Hwang BS, et al. A novel balloon-inflatable catheter for percutaneous epidural adhesiolysis and decompression. Korean J Pain 2014;27(2):178–85.
15. Choi SS, Lee JH, Kim D, et al. Effectiveness and factors associated with epidural decompression and adhesiolysis using a balloon-inflatable catheter in chronic lumbar spinal stenosis: 1-year follow-up. Pain Med 2016;17(3):476–87.
16. Lee S, Lee JW, Yeom JS, et al. A practical MRI grading system for lumbar foraminal stenosis. Am J Roentgenol 2010;194(4):1095–8.
17. Soman SM, Chokshi J, Chhatrala N, Tharadara GH, Prabhakar M. Qualitative grading as a tool in the management of multilevel lumbar spine stenosis. Asian Spine J 2017;11(2):278–84.
18. Kim DY, Lee SH, Lee HY, et al. Validation of the Korean version of the Oswestry Disability Index. Spine 2005;30(5):E123–7.
19. Dworkin RH, Turk DC, Farrar JT, et al. Core outcome measures for chronic pain clinical trials: IMMPACT recommendations. Pain 2005;113(1):9–19.
20. Farrar JT, Young JP Jr, LaMoreaux L, Werth JL, Poole RM. Clinical importance of changes in chronic pain intensity measured on an 11-point numerical pain rating scale. Pain 2001;94(2):149–58.
21. Han YJ, Lee MN, Cho MJ, Park HJ, Moon DE, Kim YH. Contrast runoff correlates with the clinical outcome of cervical epidural neuroplasty using a Racz catheter. Pain Physician 2016;19(7):E1035–40.
22. Lee SH, Kim JM, Chan V, Kim HJ, Kim HI. Ultrasound-guided cervical periradicular steroid injection for cervical radicular pain: Relevance of spread pattern and degree of penetration of contrast medium. Pain Med 2013;14(1):5–13.
23. Weinstein JN, Lurie JD, Tosteson TD, et al. Surgical versus nonsurgical treatment for lumbar degenerative spondylolisthesis. N Engl J Med 2007;356(22):2257–70.
24. Porter RW. Spinal stenosis and neurogenic claudication. Spine 1996;21(17):2046–52.
25. Ackerman WE, Ahmad M. The efficacy of lumbar epidural steroid injections in patients with lumbar disc herniations. Anesth Analg 2007;104(5):1217–22.
26. Kim JH, Jung HJ, Nahm FS, Lee PB. Does improvement in epidurography following percutaneous epidural neuroplasty correspond to patient outcome? Pain Pract 2015;15(5):407–13.

Downloaded from https://academic.oup.com/painmedicine/article-abstract/21/4/677/5570559 by Univ of Ulsan, College of Med, Medical Library user on 16 April 2020

27. Shin JW. Is epidurogram a reliable tool for the diagnosis of epidural adhesion? Korean J Pain 2012;25 (2):133–4.
28. Jo DH, Jang S. The correlation between caudal epidurogram and low back pain. Korean J Pain 2012;25 (1):22–7.
29. Manchikanti L, Cash KA, McManus CD, Pampati V, Abdi S. Preliminary results of a randomized, equivalence trial of fluoroscopic caudal epidural injections in managing chronic low back pain: Part 4—spinal stenosis. Pain Physician 2008;11(6):833–48.
30. Takeshima N, Miyakawa H, Okuda K, et al. Evaluation of the therapeutic results of epiduroscopic adhesiolysis for failed back surgery syndrome. Br J Anaesth 2009;102(3):400–7.
31. Lee JH, An JH, Lee SH. Comparison of the effectiveness of interlaminar and bilateral transforaminal epidural steroid injections in treatment of patients with lumbosacral disc herniation and spinal stenosis. Clin J Pain 2009;25(3):206–10.
32. Manchikanti L, Abdi S, Atluri S, et al. An update of comprehensive evidence-based guidelines for interventional techniques in chronic spinal pain. Part II: Guidance and recommendations. Pain Physician 2013;16(2 Suppl):S49–83.

Downloaded from https://academic.oup.com/painmedicine/article-abstract/21/4/677/5570559 by Univ of Ulsan, College of Med, Medical Library user on 16 April 2020